



Case Report

First Meniscal Radial Tear Repair Using Intraarticular Small Extracellular Vesicles from Clonal Immortalized Mesenchymal Stromal Cells

Arne Jensen^{1,3*}, Joachim Schubert², Metin Colpan³

¹Campus Clinic Gynecology, Ruhr-University Bochum, Universitätsstr. 136, 44799 Bochum, Germany

²ATOS MVZ Orthopedic Clinic, Viktoriastr. 66, 44787 Bochum, Germany

³X-osome Therapeutics UG Bochum Universitätsstr. 136, 44799 Bochum, Germany

***Corresponding author:** Arne Jensen, Campus Clinic Gynecology, Ruhr-University Bochum, Universitätsstr. 136, 44799 Bochum, Germany

Citation: Jensen A, Schubert J, Colpan M (2025) First Meniscal Radial Tear Repair Using Intraarticular Small Extracellular Vesicles from Clonal Immortalized Mesenchymal Stromal Cells. Ann Case Report. 10: 2200. DOI:10.29011/2574-7754.102200

Received: 22 February 2025, **Accepted:** 25 February 2025, **Published:** 28 February 2025

Abstract

One of the most common injuries of the knee are meniscal tears amounting to 0.61-0.70 per 1,000 person-years. Of these, meniscal radial tears have a particular poor prognosis. Here we present a Case Report of an elderly long-distance runner patient with a full thickness radial tear of the right knee who was successfully treated using bone marrow small extracellular vesicles (EVs) from clonal immortalized mesenchymal stromal cells for the first time. After characterisation, we injected intraarticularly the cell equivalent of 10e6 EVs (diameter 50-150µm) derived from bone marrow clonal immortalized mesenchymal stromal cells (ciMSCEVs) that were previously tested in vitro and in vivo for their anti-inflammatory capacity and neuro-regenerative potential. After one application only, the patient experienced complete recovery and a full restoration of meniscal continuity (scarring) and function by intraarticular injection of ciMSCEVs. Extracellular vesicles from mesenchymal stromal cells hold significant promise as a cell-free therapeutic approach for meniscal repair and cartilage regeneration.

Keywords: Evs From Clonal Immortalized Mesenchymal Stromal Cells; Small Extracellular Vesicles; Meniscal Repair; Medial Meniscal Radial Tear.

Significance Statement

The first meniscal repair with full restoration of function using ciMSC EVs holds significant promise as a cell-free therapeutic approach

Introduction

One of the most common injuries of the knee are meniscal tears amounting to 0.61 - 0.70 per 1,000 person-years in the US population [1]. Of these, meniscal radial tears are associated

with a particular poor prognosis, leading to meniscal extrusion, intraarticular cartilage loss, and early osteoarthritis [2,3].

Surgery aims at repairing the meniscus posterior horn root tear, the most common meniscal injury in association with extrusion, to restore meniscal function. This involves at times the release of the peripheral attachments of the extruded meniscus by centralization [4], using various suture techniques [5,6].

Interestingly, predictors of progression of osteoarthritis are the presence of meniscal extrusion (P=0.001), severe medial tear (P=0.005), medial or lateral bone edema (P<0.005), and age [7].

Since a greater tear gap and meniscal extrusion cause loss of chondroprotective function of the meniscus and progression of osteoarthritis, outcome is poor [8]. Therefore, various surgical techniques, including refixation of medial meniscal posterior root tears or partial meniscectomy have been employed, albeit with limited benefit [9].

Recently, beyond platelet rich plasma therapy, a cellular approach using mesenchymal stromal cells and/or their exosomes derived from autologous fat tissue has been advocated [10]. However, cell processing and quality control are challenging as are senescence or oncogenic potential with increasing numbers of passages [11].

These production issues hampering existing research in similar areas have been overcome in the present study by immortalizing mesenchymal stromal cells derived from pooled donors bone marrow using hTERT technology and testing the various clones for their immunomodulatory capacities. This is essential to overcome potential limitations of batch-to-batch variations [11]. After proven immunomodulatory capacity, the clones were used to harvest their EVs (50-150 μ in diameter). These were tested in vivo in a mouse HI model and showed significant neuro-regenerative potential [12]. Thereafter, we used the same batch of ciMSC EVs tested in vitro and in vivo to perform an individual treatment by intraarticular injection in an elderly patient who suffered from a full thickness radial medial meniscal tear of the right knee.

Methods

Cultivation of MSCs and preparation of MSCs EVs

Primary MSCs were raised and characterized as previously described [13]. Briefly, cells of given MSC stocks (MSC41.5, ciMSC 41.5 clone 6) were expanded at 37°C in a 5% CO₂ atmosphere in DMEM low glucose (PAN Biotech, Germany), supplemented with 10% human platelet lysate (hPL), 100 U/ml penicillin-streptomycin-glutamine (ThermoFisher Scientific, Germany), and 5 IU/ml heparin (Ratiopharm, Germany). In total, 2 \times 10⁷ cells were seeded in Nunc EasyFill Cell Factory System (ThermoFisher Scientific) and raised in 400-ml culture medium. As soon as MSCs reached a density of approximately 50% confluency, the culture media were exchanged, and conditioned media (CM) were harvested every 48 h until passaging, i.e., when MSCs reached 80-90% confluency. CM were cleared from residual cells and debris by 2,000 \times g centrifugation for 15min (Rotor:JS-5.3; Beckman-Coulter, Germany), and supernatants were stored at -20°C until further processing. CMs were screened regularly for mycoplasma contamination (VenorGeM OneStep, MinervaBiolabs, Germany). EVs were prepared from thawed pooled CMs according to our standard procedure, i.e., by polyethylene glycol 6000(PEG) precipitation followed by ultracentrifugation. EVs were solved in 10mM HEPES 0.9%NaCl buffer (ThermoFisher Scientific) and

stored at -80°C as 1-ml aliquots containing EVs harvested from CMs of 4 \times 10⁷ MSCs. The batch of ciMSC EV 41.5 clone 6 used in this study was prepared from a 1.2-1 pool of CMs harvested from passages 34 to 37 corresponding to a total cell equivalence of 1.92 \times 10⁸ cells. The primary MSC-EV 41.5 batch was prepared from a 4.4-1 pool of passages 4 to 5 CMs corresponding to a cell equivalent of 6.45 \times 10⁸ cells.

MSC characterization

The ciMSCs were analysed according to the criteria of the International Society of Cell and Gene Therapy (ISCT) [14]. Morphology and the osteogenic and adipogenic differentiation potential of MSCs were analysed as described previously [13,15]. Cell surface phenotypes of EV-producing MSCs were analysed by flow cytometry (CytoFLEX; Software CytExpert 2.3, Beckman-Coulter) following anti-CD14, anti-CD31, anti-CD34, anti-CD44, anti-CD45, anti-CD73, anti-CD90, anti-CD105, and anti-HLA-DR antibody staining.

EV characterization

Obtained MSC-EV preparations were characterized according to the recommendation of Minimal Information for Studies of Extracellular Vesicles 2018(MISEV2018) criteria. Briefly, particle concentrations were measured by nanoparticle tracking analysis on a Zeta View platform (Particle Metrix, Germany) [17,18]. The protein concentration was assessed using the bicinchoninic acid (BCA) assay (Pierce, IL, USA) according to the manufacturer's recommendations. Characterization of EV marker expression was performed as previously described [19,20]. Briefly, 5 μ l of PEG-UC-prepared EV samples was labelled with anti-CD9, anti-CD63, and anti-CD81 antibodies. Unstained samples and buffer without EVs but with antibodies were used as controls. All samples were incubated for 1h in the dark at room temperature, followed by dilution in PBS (pH 7.4; Gibco) (100-fold for anti-CD9 and 40-fold for anti-CD63 or CD81). Samples were analysed with an ImageStreamX Mark II instrument (Amnis/Luminex, USA). All data were acquired for 5 min at 60 x magnification and low flow rate (0.3795 \pm 0.0003 μ l/min). Data analyses were performed using IDEAS software version 6.2 as described previously [19,20]. All fluorescent objects were plotted against the side scatter. Images were analyzed for coincidences by using the spot counting feature. Events with multiple spots were excluded from further analysis. For evaluation of the in vitro immunomodulatory function of MSC-EV products, 25- μ g protein of EV preparations was tested in a multi-donor mixed lymphocyte reaction (mdMLR) assay as previously described [21,22]. Briefly, after thawing, 6 \times 10⁵ pooled peripheral blood mononuclear cells (PBMC) of 12 donors were seeded into each well of a 96-well -bottom shape plate (Corning, Germany). Cells were cultured in the presence or absence of EV or control samples in 200- μ l RPMI 1640 supplemented with

100U/ml penicillin, 100pg/ml streptomycin (all ThermoFisher Scientific), and 10% human AB serum for 5 days at 37°C in a 5% CO₂ atmosphere. For analyses, cells were harvested and labelled with an antibody cocktail of anti-CD4, anti-CD8, anti-CD25, and anti-CD54 antibodies. Analyses were performed on a CytoFLEX flow cytometer (Software CytExpert2.3, Beckman-Coulter). T cells were identified as CD4+ or CD8+ cells. Activated CD4 and CD8 cells were identified as CD25 and CD54 double-positive cells

Multidonor mixed lymphocyte reaction (mdMLR) assay

The immunomodulatory activities of samples of the obtained iMSC-EV preparations were evaluated within the mdMLR assay exactly as described previously [23]. Briefly, peripheral blood mononuclear cells (PBMCs) from 12 different donors were isolated by conventional Ficoll density gradient centrifugation and pooled using identical cell numbers from each donor. Aliquots of PBMC pools were stored in the vapor phase of liquid nitrogen until usage. Upon thawing, PBMCs were cultured in RPMI 1640 medium (ThermoFisher Scientific) supplemented with 10% human AB serum (produced in-house), 100 U/ml penicillin, and 100 g/ml streptomycin (ThermoFisher Scientific). A total of 6x10⁵ cells in a final volume of 200µl per well were cultured at 37°C and a 5% CO₂ atmosphere in the presence or absence of iMSC-EV preparations in 96-well U-bottom Falcon plates, respectively. For functional testing, 5 µl of given iMSC-EV preparations were applied to the respective wells. After 5 days of culture, the cells were harvested and stained with a cocktail of fluorescently labelled antibodies: anti-CD4, anti-CD8, anti-CD25 and anti-CD54. Dead cells were identified as 7-aminoactinomycin-D (Beckman-Coulter) incorporating cells. Data acquisition was performed on a CytoFLEX flow cytometer with CvtExpert 2.3 software (Beckman-Coulter). The obtained data were analysed with Kaluza Analysis 2.1 software (Beckman-Coulter).

Medical History

The long-distance runner patient (half-marathon), 71 years of age, (A.J.) suffered from undefined knee problems on the right-side during training. An MRI on 09-19-2022 of the right knee joint revealed medial and lateral chondromalacia grade III-IV and grade II, respectively, minor joint effusion and a narrow horizontal basal tear with suspicion of a small incomplete radial tear of the intermediate part of the medial meniscus (not shown). Physiotherapy proved successful transiently, however, when muscle building was combined with deep squats, knee problems on the right increased causing severe pain and limping.

A second MRI on 04-27-2023 of the right knee joint revealed significant deterioration of findings, including swelling, a new-onset medial and lateral bone edema of the tibia plateau, increased chondromalacia grade III-IV and joint effusion, meniscal extrusion, a large Baker cyst, and a full thickness radial medial meniscal tear (tear gap of wound edges apical/femoral 5.4mm and distal/tibial 3.4mm) requiring antiphlogistic medication and physical immobilisation (Figure 1 a,b). Due to hardly any improvement of the symptoms and after written consent was obtained, the decision was taken to once inject ciMSC derived extracellular vesicles (ciMSC EVs equivalent to 10⁶ MSC cells in 250µl diluted to 1ml isotonic 0.9% NaCl solution) intraarticularly into the right knee on 07-20-2023 after local anesthesia (J.S.).

Results

Therapy was well tolerated, antiphlogistic medication was discontinued, and pain as well as limping was significantly reduced. Six weeks after ciMSC EVs injection, there was no pain and gait returned to normal without joint stiffness in the right knee. The control MRI examination 10 weeks and 6 months after the ciMSC EVs injection revealed the reconstitution of the medial meniscal radial tear by scarring in that the meniscal wound edges were reunited, thus, restoring the continuity of the meniscus. Functionally, there was continued complete restoration with no discomfort when walking to such an extent that long-distance running training was resumed.

Imaging

Before EVs treatment, MRI imaging on 04-27-2023 showed meniscal extrusion, massive bone edema, peripatellar effusion, and a large Baker cyst of 5.1x2.05cm(a), and a full thickness medial meniscal radial tear(b), (Figure 1 a,b). Ten weeks after EVs treatment, MRI imaging on 10-02-2023 showed improvement in various domains: narrow vertical scar (~1mm) of the former full thickness medial radial meniscal tear, eliminated bone edema in tibia head and femoral condyles, reduced peripatellar effusion, and greatly reduced size of Baker cyst (that almost vanished) as compared with MRI imaging 04-27-2023 (Figure 2a,b).

MRI imaging on 19-01-2024, 6 months after ciMSC EVs injection showed further improvement in various domains: narrow vertical consolidated scar (1-2mm) of the former full thickness radial meniscal tear, eliminated bone edema in tibia head and femoral condyles, no osteoarthritis, no peripatellar effusion, and greatly reduced size of Baker cyst as compared with MRI imaging 04-27-2023 (Figure 3a,b).

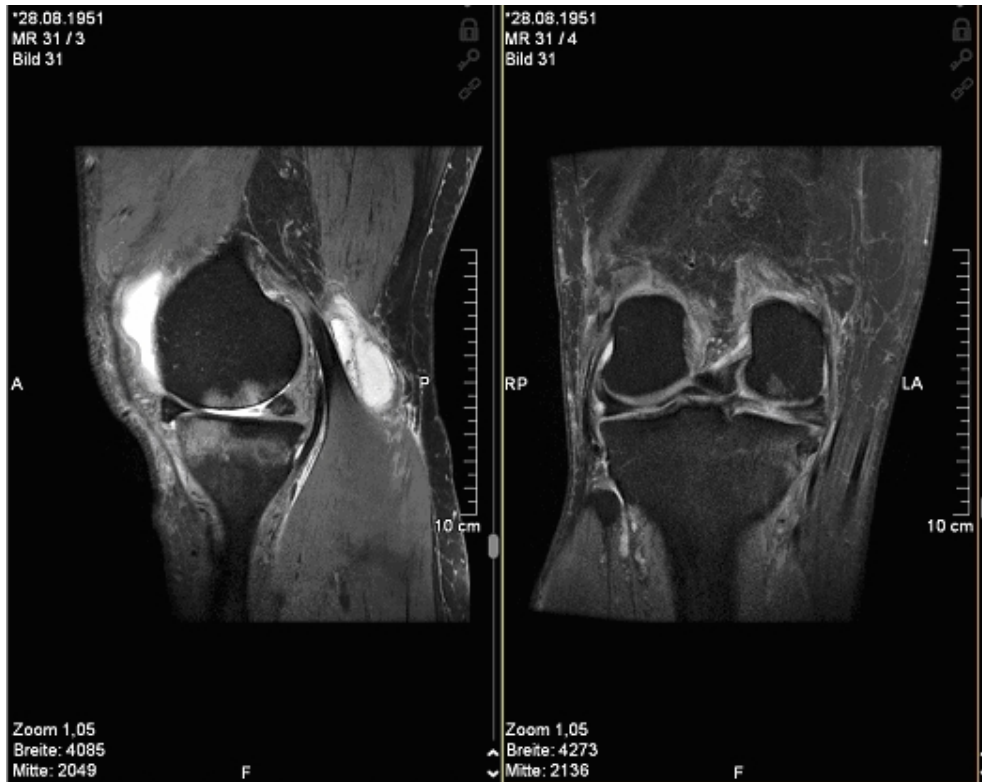


Figure 1a, b: MRI before treatment on 04-27-2023: (a) Meniscal extrusion, massive bone edema, peripatellar effusion, and a large Baker cyst of 5.1x2.1cm. (b) Large full thickness meniscal radial tear gap and bone edema (gray areas) in femoral condyle and tibial plane.

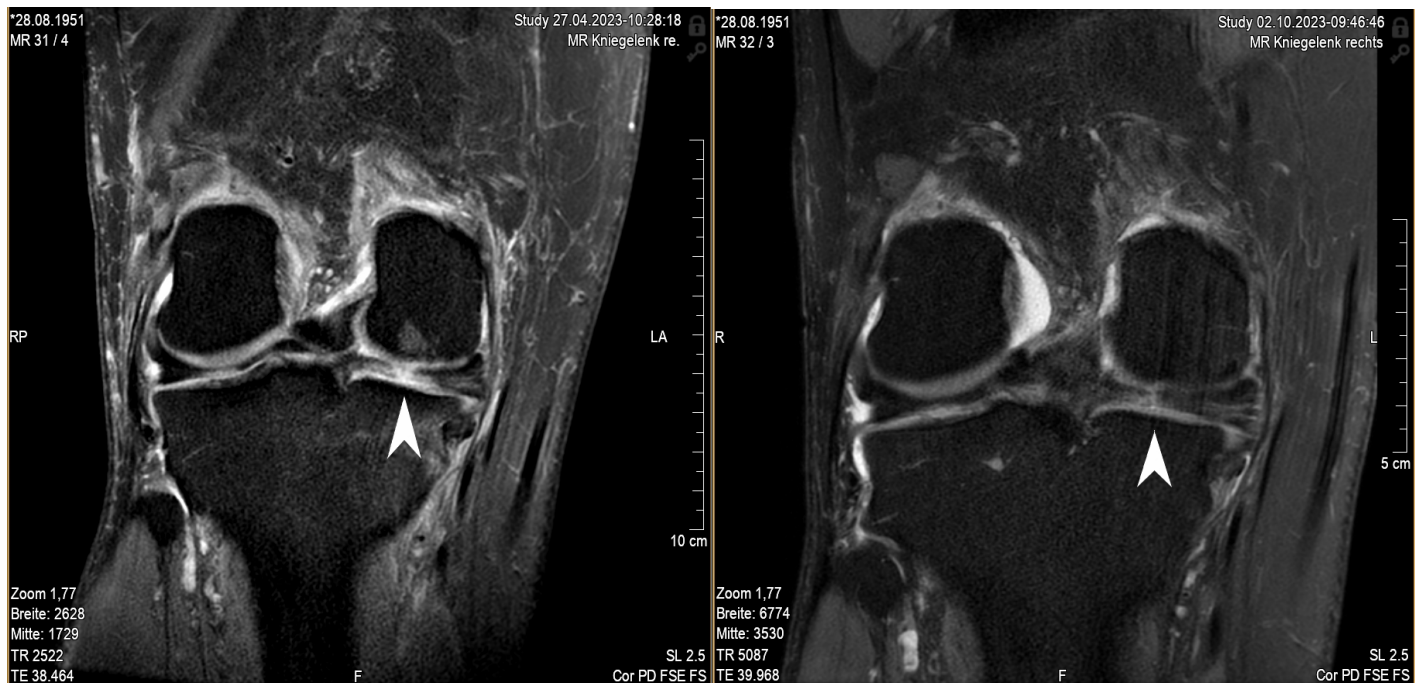

Figure 2a, b: MRI before treatment with ciMSC EVs on 04-27-2023 (a): Large tear gap (arrow) along with bone edema and effusion. (b) MRI 10 weeks after treatment with ciMSC EVs on 10-02-2023: Improvement in various domains. Small radial meniscal tear gap scar (arrow), restored meniscal continuity, eliminated bone edema in the tibia head and condyles, reduced peripatellar effusion, and greatly reduced size of Baker cyst (almost vanished).

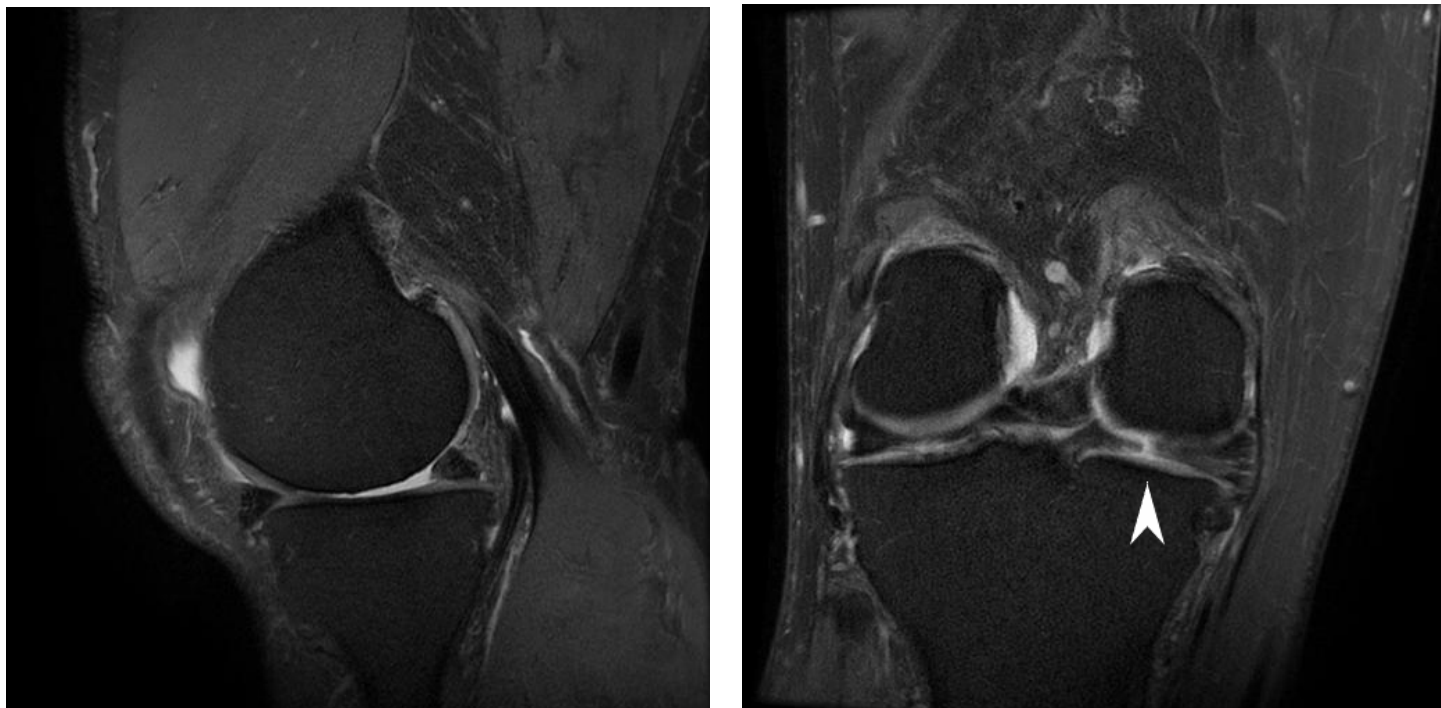


Figure 3a, b: MRI imaging of the right knee joint 6 months after treatment on 19-01-2024. Further improvement in various domains: (a) slightly reduced meniscal extrusion and minimal cartilage regeneration (gray border) between meniscus and femoral condyle. (b) Narrow vertical consolidated scar (1-2mm) of the former full thickness radial meniscal tear (arrow), eliminated bone edema in tibia head and femoral condyles, no osteoarthritis, no peripatellar effusion, and greatly reduced size of Baker cyst as compared with MRI imaging before treatment.

Discussion

To the best of our knowledge, this is the first individual trial in which a full thickness radial medial meniscal tear was successfully treated by small Extracellular Vesicles (EVs <150µm in diameter) derived from bone marrow clonal immortalized mesenchymal stromal cells, previously tested for immunomodulatory and neuroregeneration capacities in a mouse model, with full restoration of function in an elderly long-distance runner (A.J.) [12].

Beyond the impressive scarring of the meniscal full thickness tear with restoration of the structural continuity and integrity, the anti-inflammatory effect of the EV treatment on bone edema is conspicuous. Despite chondromalacia grade III-IV in the MRI, there are no signs of osteoarthritis, swelling, or effusion, and when walking or running there was no pain, joint stiffness, or unsteady gait so that training could be resumed without discomfort.

The present results in man corroborate previous experimental evidence of meniscal repair in mice by extracellular vesicles derived from mesenchymal stromal cells involving endogenous cell growth and migration via the CXCL5 and CXCL6/CXCR2 axes [24].

There are significant advantages of EVs over cell-based therapy, including EVs less stringent storage conditions compared to live cells, simplifying treatment logistics, and reducing costs

[25]. Furthermore, MSC exosomes promote cartilage repair by regeneration of osteochondral defects and alleviating osteoarthritis degeneration [25]. Studies have shown that exosomes derived from mesenchymal stromal cells (MSCs) from various sources can effectively support cartilage regeneration by stimulating chondrocyte proliferation, differentiation, and ECM synthesis [25,26]. Also, EVs allow for allogeneic transplantation due to their lack of MHC I and II antigens with potential for off-the-shelf use of EVs from various donors, overcoming limitations of autologous cell therapies. Due to the reduced susceptibility, EVs are more resistant to damage at the injury site compared to fragile cells, improving their therapeutic efficacy. Importantly, there is a lower tumorigenicity risk because EVs are non-replicating in nature and hence, the use of EVs reduces the risk of tumor formation that is associated with certain stem cell therapies.

With respect to the present case report, in which a substantial anti-inflammatory effect and meniscal scarring was observed, it is noteworthy that EVs have been shown to modulate inflammation by regulating macrophage polarization, potentially delaying or preventing osteoarthritis progression [26], as well as promoted production of key ECM components like collagen type II and proteoglycans, contributing to cartilage homeostasis [27]. Also, specific miRNAs within EVs can promote chondrocyte proliferation, further aiding in cartilage repair [26].

Conclusion

EVs hold significant promise as a cell-free therapeutic approach for cartilage repair. Their advantages over cell-based therapies, combined with evidence supporting their efficacy in promoting cartilage regeneration and modulating inflammation, make them a valuable avenue for further research and development. Addressing the identified challenges will be crucial for realizing the full potential of EVs in clinical applications.

Patient Consent Statement: “Patient consent was obtained”

Conflict of Interest: “The authors report no conflict of interest”

Funding: “Horus Ventures GmbH, Düsseldorf”

Acknowledgement

The ciMSC-EVs derived from bone marrow used in this individual treatment were kindly provided by the Institute for Transfusion Medicine, University Hospital Essen, University of Duisburg-Essen, Essen, Germany.

References

1. Mameri ES, Jackson GR, Gonzalez F, Kaplan DJ, Jawanda H, et al (2023) Meniscus Radial Tears: Current Concepts on Management and Repair Techniques *Current Reviews in Musculoskeletal Medicine*.16:182–19.
2. Jarraya M, Roemer FW, Englund M, Crema MD, Gale HI, et al (2017) Meniscus morphology: Does tear type matter? A narrative review with focus on relevance for osteoarthritis research *Semin Arthritis Rheum*. 46:552-561.
3. Gajjar SM, Solanki KP, Kambhampati SBS (2021) Meniscal Extrusion A Narrative Review. *The Orthopaedic Journal of Sports Medicine*, 9: 232596712111043797.
4. Ozeki N, Nakamura T, Nakagawa Y, Sekiya I, Koga H (2023) Meniscus repair and centralization: Preserving meniscus function *Journal of Joint Surgery and Research*, 1:46-55.
5. Chernchujit B, Agrawal S (2019) Arthroscopic All-Inside Medial Meniscus Extrusion Reduction Arthroscopy Techniques, 8: e495-e501.
6. Paletta GA, Crane DM, Konicek J, Piepenbrink M, Higgins LD, et al (2020) Surgical Treatment of Meniscal Extrusion - A Biomechanical Study on the Role of the Medial Meniscotibial Ligaments with Early Clinical Validation *The Orthopaedic Journal of Sports Medicine*, 8: 2325967120936672.
7. Renaud J-P, Jean-Pierre, Martel-Pelletier J, Berthiaume M-J, Beaudoin G, et al (2006) Long term evaluation of disease progression through the quantitative magnetic resonance imaging of symptomatic knee osteoarthritis patients: correlate on with clinical symptoms and radiographic changes *Arthritis Research & Therapy*. 8:R21.
8. Kim J-Y, Bin S-I, Kim J-M, Lee B-S, Oh S-M, et al (2019) Tear gap and severity of osteoarthritis are associated with meniscal extrusion in degenerative medial meniscus posterior root tears *Orthopaedics & Traumatology: Surgery & Research*. 105:1395-1399.
9. Chung KS, Ha JK, Yeom CH, Ra HJ, Jang HS, et al (2015) Comparison of Clinical and Radiologic Results Between Partial Meniscectomy and Refixation of Medial Meniscus Posterior Root Tears: A Minimum 5-Year Follow-up Arthroscopy. 31:1941-50.
10. Jeyaraman M, Muthu S, Ganie PA (2021) Does the Source of Mesenchymal Stem Cell Have an Effect in the Management of Osteoarthritis of the Knee? Meta-Analysis of Randomized Controlled Trials *CARTILAGE*. 13: 1532S –1547S.
11. Tertel T, Dittrich R, Arsène P, Jensen A, Giebel B (2023) EV products obtained from iPSC-derived MSCs show batch-to-batch variations in their ability to modulate allogeneic immune responses in vitro *Front. Cell Dev. Biol*. 11:1282860.
12. Labusek N, Mouloud Y, Köster C, Diesterbeck E, Tertel T, et al (2023) Extracellular vesicles from immortalized mesenchymal stromal cells protect against neonatal hypoxic-ischemic brain injury *Inflammation and Regeneration*. 43:24.
13. Radtke, S, Gorgens, A, Liu, B, Horn, P. A, and Giebel, B. (2016) Human mesenchymal and murine stromal cells support human lymphomyeloid progenitor expansion but not maintenance of multipotent haematopoietic stem and progenitor cells. *Cell Cycle* 15: 540–545.
14. Dominici M, Le Blanc K, Mueller I, Slaper Cortenbach I, Marini F, et al. (2006) Minimal criteria for defining multipotent mesenchymal stromal cells. The International Society for Cellular Therapy position statement. *Cytotherapy*. 8:315–7.
15. Kordelas L, Rebmann V, Ludwig AK, Radtke S, Ruesing J, et al. (2014) MSC derived exosomes: a novel tool to treat therapy refractory graft versus host disease. *Leukemia*. 28:970–3.
16. Thery C, Witwer KW, Aikawa E, Alcaraz MJ, Anderson JD, et al. (2016) Minimal information for studies of extracellular vesicles 2018 (MISEV2018): a position statement of the International Society for Extracellular Vesicles and update of the MISEV2014 guidelines. *J Extracell Vesicles*. 7:1535750.
17. Sokolova V, Ludwig AK, Hornung S, Rotan O, Horn PA, et al. (2011) Characterisation of exosomes derived from human cells by nanoparticle tracking analysis and scanning electron microscopy. *Colloids Surf B Biointerfaces*. 87:146–50.
18. Dragovic RA, Gardiner C, Brooks AS, Tannetta DS, Ferguson DJ, et al. (2011) Sizing and phenotyping of cellular vesicles using nanoparticle tracking analysis. *Nanomedicine*. 7:780–8.
19. Tertel T, Bremer M, Maire C, Lamszus K, Peine S, et al. (2020) High-resolution imaging flow cytometry reveals impact of incubation temperature on labeling of extracellular vesicles with antibodies. *Cytometry A*. 97:602–9.
20. Tertel T, Gorgens A, Giebel B. (2020) Analysis of individual extracellular vesicles by imaging flow cytometry. *Methods Enzymol*. 645:55–78.
21. Madel RJ, Börger V, Dittrich R, Bremer M, Tertel T, et al. (2020) Independent human mesenchymal stromal cell derived extracellular vesicle preparations differentially affect symptoms in an advanced murine graft versus host disease model. *bioRxiv*. 12:423658.
22. Bauer FN, Tertel T, Stambouli O, Wang C, Dittrich R, et al. (2023) CD73 activity of mesenchymal stromal cell derived extracellular vesicle preparations is detergent resistant and does not correlate with immunomodulatory capabilities. *Cytotherapy*. 25:138–47.
23. Bauer N, Giebel B. (2021) Therapeutic Potential of Mesenchymal Stromal Cell derived Small Extracellular Vesicles F. In book: *Extracellular Vesicles*. The Royal Society of Chemistry. 2021.
24. Kawata K, Koga H, Tsuji K, Miyatake K, Nakagawa Y, et al (2020) Extracellular vesicles derived from mesenchymal stromal cells mediate endogenous cell growth and migration via the CXCL5 and CXCL6/CXCR2 axes and repair menisci. *Stem Cell Res Ther*. 12:414.
25. Tan SSH, Tjio CKE, Wong JRY, Wong KL, Chew JRJ, et al (2021) Mesenchymal Stem Cell Exosomes for Cartilage Regeneration: A Systematic Review of Preclinical In Vivo Studies. *Tissue Eng Part B Rev*. 27:1-13.

Citation: Jensen A, Schubert J, Colpan M (2025) First Meniscal Radial Tear Repair Using Intraarticular Small Extracellular Vesicles from Clonal Immortalized Mesenchymal Stromal Cells. *Ann Case Report*. 10: 2200. DOI:10.29011/2574-7754.102200

26. Ma K, Zhu B, Wang Z, Cai P, He M, et al (2020) Articular chondrocyte-derived extracellular vesicles promote cartilage differentiation of human umbilical cord mesenchymal stem cells by activation of autophagy. *J Nanobiotechnology*. 18:163.
27. He L, He T, Xing J, Zhou Q, Fan L, et al (2020) Bone marrow mesenchymal stem cell-derived exosomes protect cartilage damage and relieve knee osteoarthritis pain in a rat model of osteoarthritis. *Stem Cell Res Ther*, 11: 276.